


CORNEAL ULCERS IN DOGS



UPTAKE OF FLUORESCEIN TO THE CORNEA

UNCOMPLICATED ULCER

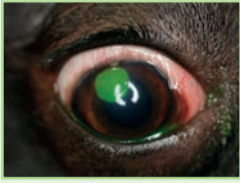
Superficial defects should heal within hours to days with appropriate treatment!

Treatment consists of supportive medical therapy:

- Topical antimicrobial therapy**
 - Broad spectrum, minimal epithelial cell toxicity is best
- Ocular lubricant**
 - Oculenis™ BioHAnce™ Ocular Repair Gel: 1 to 2 drops BID**
- Analgesia**
 - Oral NSAIDs +/- opioids
 - Topical atropine 1% if iridial spasm present – use no more than BID for 1-2 days. Aim for mid-dilated pupil size. Take care in small patients due to systemic side effects. Take care in patients with KCS (will reduce tear production)
 - Avoid topical anesthetics (epitheliotoxic) and corticosteroids due to delayed healing/corneal melting (due to induction of host collagenolytic enzymes)
- Elizabethan collar to prevent self-trauma if indicated**

CORNEAL ULCER

- Clinical signs – lacrimation, photophobia, blepharospasm, conjunctival erythema, corneal opacity (due to corneal edema), vascularization of cornea +/- anterior uveitis (miotic pupil, aqueous flare, iris synechia, change in iris color, decrease in IOP initially)



Etiology:

- Primary – SCCED (spontaneous chronic corneal epithelial defect), corneal degeneration, punctate keratitis
- Secondary – Structural (distichiasis, trichiasis, ectopic cilia, lagophthalmos, other eyelid abnormalities), foreign body, trauma, viral (feline herpes virus), quantitative or qualitative tear film deficiencies (dry eye disease), corneal irritants (heat, smoke, acid, alkalis), neurological disease (neurotrophic keratopathy, facial nerve paralysis)
- Bacterial or fungal keratitis likely requires corneal damage to allow colonization

UNDERRUNNING OF FLUORESCEIN UNDER EPITHELIUM

SCCED ULCER (SPONTANEOUS CHRONIC CORNEAL EPITHELIAL DEFECT)

- AKA boxer/indolent/chronic superficial/refractory ulcer or canine recurrent erosions
- Clinical signs: see 'corneal ulcer' – ocular discomfort variable, loose edges of epithelium surrounding denuded corneal stroma (shown by underrunning of fluorescein stain)
- Can persist for weeks to months
- More common in middle-aged to older dogs
- Boxers are over-represented

Treatment

- Debridement of loose epithelium**
 - Instill topical local anesthetic
 - Use dry cotton tip applicator to gently debride loose edges
 - Grid or punctate keratotomy* OR diamond burr debridement*
- Appropriate topical antimicrobial therapy as indicated on a case-to-case basis**
- Consider use of hyaluronic acid ocular lubricant or bandage contact lens**
 - Provides comfort and reduces disruption of migrating corneal epithelial cells by blinking
 - Oculenis™ BioHAnce™ Ocular Repair Gel: 1 to 2 drops BID**
- Analgesia** (see uncomplicated ulcer)
- Elizabethan collar to prevent self-trauma if indicated**

*Not in cats (risk of forming corneal sequestrum)

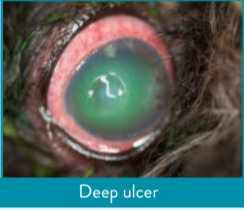
PROGRESSION IN SIZE/DEPTH

NOT HEALED WITHIN EXPECTED TIME FRAME

SCCED? RECHECK WITH FLUORESCEIN

MELTING ULCER

- Clinical appearance – opaque/gelatinous/irregular cornea, stromal loss, variable pain, as sensation may have been lost with significant destruction of cornea
- Stromal collagenolysis caused by excess of host and bacterial matrix metalloproteinases (i.e., collagenase and proteinase enzymes)
- If bacterial infection is present, *Pseudomonas* and *Streptococcus* spp. are commonly implicated (Note - ulcers can degrade even if sterile!)
- Descemetocoele - lack of fluorescein uptake at deepest part of ulcer, but often see deep stromal stain uptake around that area of no uptake centrally (the Descemet's membrane of the corneal endothelium does not take up stain and is the remaining layer of cells before perforation)



Deep ulcer

Medical treatment (ideally done in a hospital setting)

- Anti-collagenases**
 - Serum eye drops/EDTA/tetracyclines
- Topical antimicrobial therapy**
 - In-house corneal cytology can be useful (rods vs cocci) in guiding initial antibiotic choice while awaiting C&S
 - Consider adding in systemic antibiotics with good ocular penetration if there is risk for corneal perforation
- Analgesia** (see uncomplicated ulcer)
- Elizabethan collar to prevent self-trauma if indicated**
- Consider use of hyaluronic acid ocular lubricant**
 - Provides comfort and supports the tear film
 - Oculenis™ BioHAnce™ Ocular Repair Gel: 1 to 2 drops BID**

Surgical intervention

Referral for surgical management should be actioned when:

- Any ulcer ≥50% of stromal depth
- Descemetocoele
- Area of keratomalacia that enlarges/deepens despite aggressive medical management
- Rupture of the globe

COMPLICATED ULCER

- Check for persistent underlying etiology and treat as appropriate (see box above)
- Resistant bacterial infection? Swab for C&S and cytology
- Deep or melting ulcer

MELTING ULCERS: RISK FACTORS

Keratomalacia (corneal melting) develops as a complication of an existing corneal ulcer and can occur at any time point following diagnosis. Keratomalacia should be considered in any ulcer that has progressed in size or depth! Secondary bacterial infection is commonly (but not always) implicated.

Risk factors for the development of keratomalacia include:^{2,3}

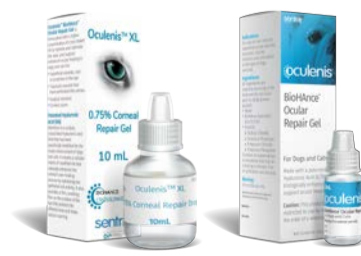- Brachycephalic conformation: up to 64% of melting ulcers in dogs are found in brachycephalic breeds
- Pre-existing ocular surface disease (e.g., KCS, lipid degeneration, SCCED, endothelial degeneration, trichiasis)
- Use of topical steroids on the cornea
- Recent general anesthesia
- Concurrent systemic disease (diabetes mellitus, hypo/hyperadrenocorticism, hypothyroidism, chronic skin diseases)
- Recent ocular surgery (e.g., keratotomy)
- Chemical injury to the cornea

Further considerations:

- Monitoring at-risk ulcers should be done more frequently (q24-48 hours)
- Corneal cytology can be useful to identify microscopic evidence of keratomalacia (neutrophils, rods, cocci)



NOTE: Oculenis™ BioHAnce™ Ocular Repair Gel contains a cross linked HA matrix that supports accelerated healing. It does not contain antibiotic or preservatives. Oculenis™ is not a one-for-one substitute for serum. Serum contains factors that can neutralize collagenase activity. Collagenases are enzymes that break the peptide bonds in collagen. They assist in destroying extracellular structures in the pathogenesis of bacteria. Thus, in complex cases of infected ulcers, serum still may be required. In addition, antibiotics are required if an infection is present. For more information, please visit sentrxanimalcare.com/learnmore



Reference: 1. D. Barritault et al. (2016) RGTA® or ReGeneraTing Agents mimic heparan sulfate in regenerative medicine: from concept to curing patients. Glycoconj J 34 325–338. 2. Tsvetanova, A., Powell, R. M., Tsvetanov, K. A., Smith, K. M., & Gould, D. J. (2021). Melting corneal ulcers (keratomalacia) in dogs: A 5-year clinical and microbiological study (2014–2018). Veterinary ophthalmology, 24(3), 265–278. 3. Guyonnet, A., Desquilbet, L., Faure, J., Bourguet, A., Donzel, E. and Chahory, S. (2020). Outcome of medical therapy for keratomalacia in dogs. J Small Anim Pract, 61: 253-258