



Wound Healing Patient Support Story


Case and Photos

PRACTICE:

Veterinary practice:
Dr. Bockholdt (treating
veterinarian: Sophie Dobbert)

PATIENT:

Patient: Moritz, 11.2
pounds, outdoor cat
Breed: European Shorthair
Gender: Male, neutered
Age: 1 year



PATIENT HISTORY:

On July 4, 2017, Moritz came home in the evening looking sluggish. He was bleeding on his right paw and had a wound on his head. His owners suspected that Moritz was hit by a car.

On July 5, 2017, Moritz was admitted to the veterinary facility.

THE PROBLEM:

ABRASION WOUND

Moritz had a large abrasion wound dorsally on his right forelimb at the level of the carpal joint and a head injury. His pads were scraped off, as well as the skin on his third and fourth toes. After a general examination, the veterinarian team completed a lateral x-ray on his abdomen and his right forelimb in two planes.

The x-rays were inconspicuous. The veterinarian team gave Moritz local anesthetics and sedation. The team carefully treated his wounds and removed his necrotic tissue.

Then they applied bandages, which were changed every two days, initially while sedating Moritz. Later, they were able to change the bandages without sedation.

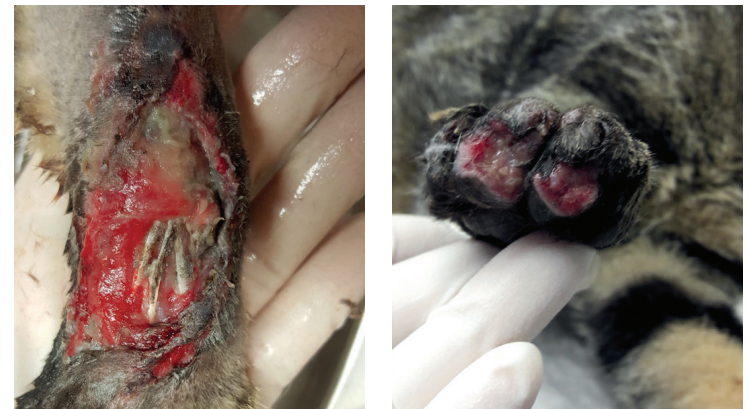

Fig. 1 and 2 Moritz at the first presentation on July 5, 2017.

THERAPY:

On July 7, 2017, the veterinarian team first applied Episanis™ BioHAnce™ Skin and Wound Gel* to clean Moritz's wounds.

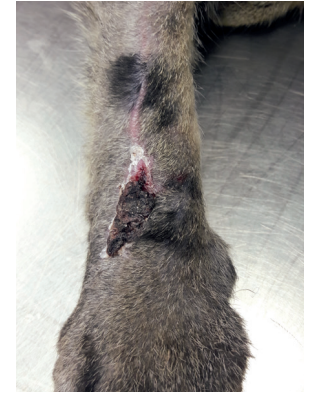
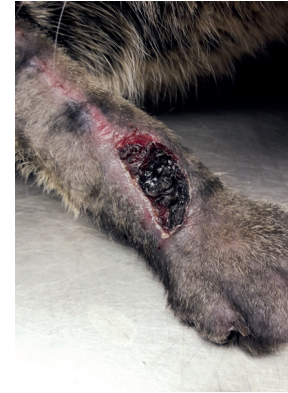
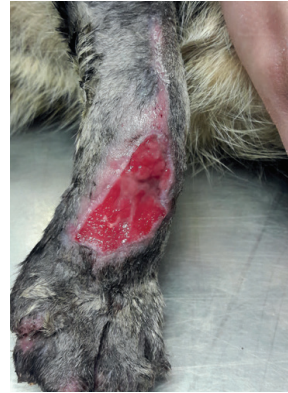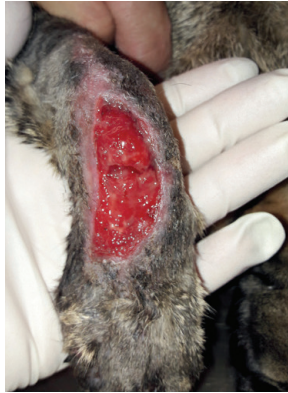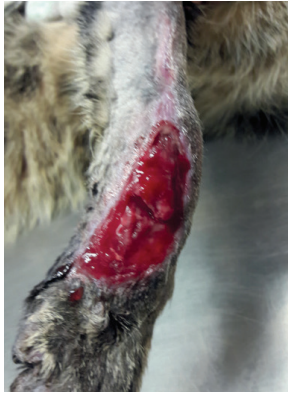Fig. 3 July 15, 2017: bandage change.
Fig. 4 July 17, 2017: bandage change.
Fig. 5 July 19, 2017: bandage change.

Fig. 6 July 22, 2017: final bandage removal.
Fig. 7 July 29, 2017: control.

THE SOLUTION: SUCCESSFUL APPLICATION OF EPISANIS BIOHANCE SKIN AND WOUND GEL*

Moritz's wound area became visibly smaller, and his re-epithelialization process was making good progress. On July 22, 2017, Moritz's owners removed his bandages for the last time and treated the remaining wounds daily with Episanis.

On September 7, 2017, Moritz had another veterinarian appointment. The skin over the healing tissue was completely closed and scar-free, and his coat already started to grow back.

The wound is covered with a film through treatment with Episanis BioHAnce Skin and Wound Gel. This method can heal small to large wounds. In this case, it took six weeks for the injury to heal completely without using additional drugs.

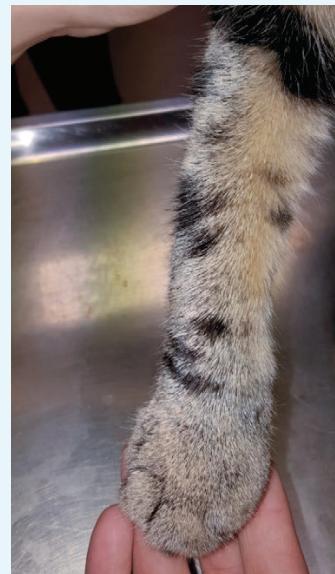
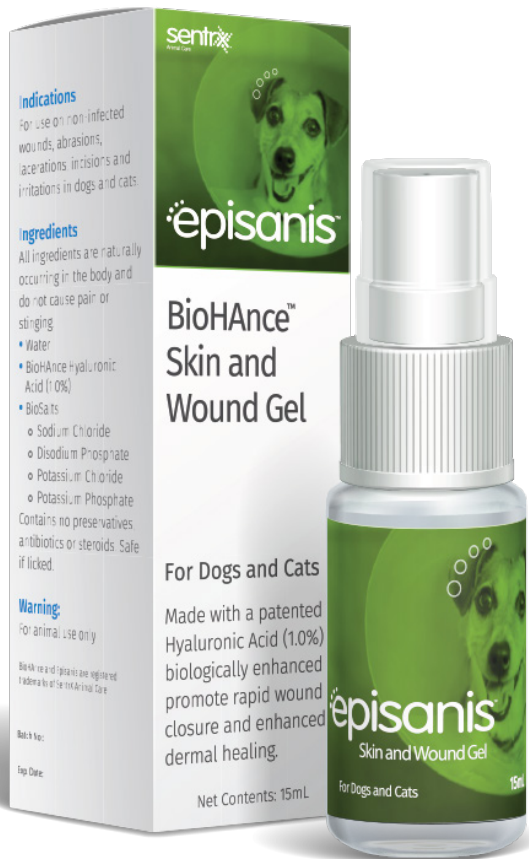
Fig. 8 September 7, 2017 checkup.

episanis
BioHAnce™ Skin and Wound Gel



episanis™

BioHance™ Skin and Wound Gel

Episanis™ contains 1.0% BioHance™ cross-linked hyaluronic acid to support accelerated healing of skin wounds. It does not contain any preservatives or antibiotics. The spray gel is soothing and easy to use with as little as one application daily.

Important Safety Information: Sentrx Animal Care does not recommend a specific plan because each case is different. A trained veterinarian should assess every treatment plan. The animal health information contained herein is provided for educational purposes only and does not replace the protocol of a trained veterinarian. This case represents an individual experience only.



Manufacturer: Sentrx Animal Care, Inc., Salt Lake City, Utah 84108

*The local name of the product used is Remend® Skin Care Spray. Episanis™ BioHance™ Skin and Wound Gel is an identical formulation and is also manufactured by Sentrx Animal Care.